Forensic Imaging 22 (2020) 200397

Contents lists available at ScienceDirect

Forensic Imaging

journal homepage: www.sciencedirect.com/journal/forensic-imaging

"Mummies outside their closets". Paleoradiological investigation of Egyptian mummified remains

Roberta Fusco[a], Marta Licata[a,*], Omar Larentis[a], Barbara Cermesoni[b], Annamaria Ravagnan[c], Rosagemma Ciliberti[d], Antonio Pinto[e], Chiara Tesi[a]

[a] Centre of Research in Osteoarchaeology and Paleopathology, Department of Biotechnology and Life Sciences, University of Insubria, Varese, Italy
[b] Civic Museums of Varese, Italy
[c] International Council of Museums' Committee for Egyptology (ICOM – CIPEG), Milan, Italy
[d] Section History of Medicine and Bioethics, Department of Science of Health, University of Genoa, Genova, Italy
[e] Department of Radiology, CTO Hospital, Azienda Ospedaliera dei Colli, Naples, Italy

ARTICLE INFO

Keywords:
Egyptian mummified remains
Paleoradiology
Museums
Paleopathology
Embalming techniques
Biparietal thinning

ABSTRACT

Paleoradiological investigations of three mummified remains housed in the archaeological museum of Erba allowed us to investigate the origin, biological profile, embalming techniques and pathological conditions of finds unknown until now. These mummified remains, belonging to the private collection of the Majnoni family, were donated to the museum without any information about their origin. We are well aware of the past issue on the commercialization of mummified remains and of the low possibility for anthropologists to have access to ancient mummies. For this reason our intent is to stimulate curators of small collections to contact team of anthropologists, radiologists and paleopathologists to grant the study of finds housed in museums with the aim of obtaining more information about the anthropological cultural heritage.

Introduction

How many times have you – physical anthropologists, pathologists, archaeologists etc. - wished to study an Egyptian mummy? Many, certainly. Also, because we know that not many researchers in the field of archaeology have access to these extraordinary preservations of human remains [1,2].

Archaeological excavations conducted in European territories, or generally in the areas of the continental planet, usually bring to light human skeletal remains from cemetery contexts [3,4]. Apart from the exception of some highly successful natural mummifications [5] of ancient human remains [6], including frozen mummies [7, 8] and bog bodies [9, 10], and of some collections of intentional mummifications, such as the crypt of the Capuchin friars in Palermo [11], the anthropologist has very few opportunities to study mummies especially those resulting from the practice of embalming [12, 13] and in particular from the evisceration of organs [14, 15].

Moreover, when this happens, of course we must use the necessary expertise of the radiologist. Radiology, or better now, Paleoradiology, is the only correct way to study mummies because it is clear that their scientific investigation must not compromise their conservation [16, 17], considering also that, given the exceptional nature of these human remains, a museum destination is envisaged [18, 19].

It is clear that finds of this type should be analysed. Overall, as often happens, if specimens have never been studied, consequently even their museum display is vitiated by the lack of descriptive information. So "mummies outside their closets" means to stimulate the study, using the updated techniques that today support anthropological analyses, of all those exhibits that have been displayed in a museum but not yet investigated. Firstly, for these specimens generally it is necessary to investigate the authenticity especially when no provenience documentation is present. In fact, the support of radiological analysis can show the type of bandage, the ornaments and the morphology of human remains (tissues and bones) [20], all to investigate if the mummy is authentic Egyptian or not.

In addition, paleoradiological investigation, through the analysis of all the materials of the mummies, allows us to adopt the better choice to preserve and expose the finds in the museum. In this regard, the analysis of an illustrative case related to the conservation of three parts of Egyptian mummies at the archaeological museum of Erba (Como-northern Italy) allows us to highlight the importance of paleoradiological investigation of human remains [21]. The finds are exhibited in a display case, inside a room dedicated to oriental studies, where various kinds of artefacts are exhibited, above all potteries and

* Corresponding author.
E-mail address: marta.licata@uninsubria.it (M. Licata).

https://doi.org/10.1016/j.fri.2020.200397
Received 19 March 2020; Received in revised form 12 June 2020; Accepted 17 July 2020
Available online 18 July 2020

ornamental objects, coming especially from private donations [22].

Our study investigated these finds through the paleoradiological analysis in order to demonstrate their authenticity, investigate the state of preservation, reveal the embalming techniques, determine their biological profile/s and to explore the possible presence of pathological conditions.

The aim of emphasizing the importance of radiological support to the bioarchaeological finds is not secondary, not only for the purposes of research but also for the expositive-informative ones.

Materials and methods

The mummified remains consist of a head, a hand and a foot. The Majnoni family donated these finds to the museum in 1977, which inherited the finds from Francesco Majnoni d'Intignano, the King's general consul in Cairo in 1902.

The decision was taken by Francesco's wife to exhibit to the community a “piece of ancient Egypt”. To accompany the finds a document that only explained the place of origin, Cairo, and nothing else, not even the way in which Majnoni took possession of them. Certainly, this aspect did not make it so easy to guarantee their authenticity until now. However, we know now that still at the beginning of the twentieth century, it was a symbol of pride, among the antique dealers, to benefit of finds such as mummies of ancient Egypt from the historical, scientific but above all emotional point of view [23, 24]. It is therefore easier to suppose that these finds had been purchased so specially divided, but it is clear that this represents only our superficial assumption. We do not know if the mummy, or mummies, arrived in Italy intact, moreover the documentation does not reveal whether these three fragments belonged to the same subject.

Only a paleoradiological investigation, according with the latest ethical standards developed for the mummified human remains, can answer these questions [25, 26].

Sex was determined on the basis of the morphological features on the skeleton [27]. Age at death was assessed through the evaluation of the degree ossification [28] and of degeneration of bone districts [29, 30].

For X-ray and CT examinations, conventional medical radiological equipment was used (GE Healthcare Revolution - GSI 128 Layers). Imaging parameters were as follows: 100 kV, 80 mA. The slice thickness used was 0.625 mm for all the pieces, reconstructed at 3 mm; for the reconstruction parameter we used the criteria suggested by Panzer and colleagues [31]. The re-elaboration of the images was performed using the software Mango (Research Imaging Institute, UTHSCSA, http://rii.uthscsa.edu/mango/mango.html) and Radiant DICOM 5.0.2 Viewer (Medixant, Poznan- Poland), which allow reconstructing 3D surfaces starting from the axial planes of CT scans acquisition.

Packaging and transport operations are essential for conducting safely analyses. Indeed, for each anatomical piece, a custom wooden box was created in order to contain it, avoiding too large spaces that would allow it to move during the transport phase. Every box was padded with inert polyester foam or pads of acid-free tissue paper. In each phase of the work, the finds were handled with disposable gloves. The wood and plastic materials used do not interfere with the TC acquisition, which can take place by not taking the sample from its box, thus avoiding unnecessary manipulation.

Results

Macroscopical description

The mummified head was composed of the skull, the mandible and the cervical trait until the 6th vertebra (Fig. 1). This part appeared almost intact, although some portions of bandages and soft tissues were missing and the skullcap was exposed. The facial portion appeared as the best preserved, covered by bandages and soft tissues, and both the auricles were well retained. The state of conservation of the head presented different degrees depending on the tissue involved. In particular, soft tissues were partly exposed as the bandages were poorly preserved and mostly lost, retaining only a few larger portions or isolated pieces. The exposed skin, mostly at the level of the mandible and lower facial portion, temporo-parietal and nuchal regions, showed a brown-black discoloration and a dehydrated appearance. Bandages, recognizable thanks to the fabric texture, were mostly preserved in the upper facial region and on the neck, while in the other areas only isolated small pieces were preserved. At the level of the skullcap, in particular of the parietals, frontal squama and of the left temporal fossa, soft tissues and bandages were missing and the bone portion was completely exposed. The observable cranial bones appeared intact without any sign of fracture or breakage. In the exposed portion, no particular modification was noted. The nasal portion of the soft tissues has also not been preserved and the piriform cavity and part of the nasal bones were exposed. At the level of the oral and nasal cavities, a resinous black substance, with a vitreous, shiny and transparent appearance was observed.

The second mummified part was comprised of the left foot and of a distal residual of the left tibia and fibula (Fig. 2). The proximal interruption of the residual limb, approximately at the level of the metaphyseal end, was jagged and irregular, exposing the section of the two bones and of surrounding tissues. From a superior view, was possible to recognize the two bone portions and a bundle of dehydrated fibres, which departed vertically from the posterior portion of the calcaneus. This element was also visible in posterior norm, as in this region bandages were missing exposing the underlying tissues. The preservation of foot bones was not evaluable as this part was almost totally covered by soft tissues and bandages. The postero-medial portion of the foot, from the calcaneus up to the medial malleolus, did not preserve bandages and a small part of black discoloured skin was exposed. The foot appeared almost complete from the tarsal to the phalangeal portion, with the exception of the second and third toes, which were missing and broken at the level of the metatarsal heads, exposing the section of the two metatarsals and of surrounding tissues. On the residual foot toes, bandages were mostly missing preventing from evaluating the wrapping pattern of these parts. The first toe, uncovered by the bandages, showed black discoloured skin and the presence of the nail.

Some blue-green tube-shaped beads were observed adhering to the bandages on the back of the foot, stuck through the coating of a whitish cementing material. This cementing material was found longitudinally along the entire back of the foot and transversely in at least two bands that crossed the back of the foot from one side to the other, indicating that, probably, at one time, the whole foot along these bands was decorated by the presence of beads, of which today only four are preserved. These beads are consistent with blue faience tubes, a particular type of fine tin-glazed pottery.

The mummified left hand comprised some of the carpals and all the metacarpals and phalanges. Macroscopically, the hand appeared almost complete and showed all the fingers individually wrapped. In particular, the entire palm of the hand appeared wrapped entirely with several turns of bandages, while the fingers, including the thumb, were individually bandaged with accuracy. Soft tissues of the hand could be evaluated only in a small portion at the level of the wrist, where the embalmed part appeared interrupted, exposing the residual carpal bones. At this level, a small part of black discoloured skin was exposed by the missing bandages. The bandages were well preserved throughout the hand and on the dorsal portion a part seemed coated with a sort of white-coloured hard covering material (Fig. 3).

In all the three specimens, a more detailed observation of the bandages revealed that they presented a plain weave, with weft and warp characterized by simple crossings. In some bandages, the threads appeared coarser and woven in a loose-weave, while other bands showed a finer and tighter weave (Figs. 1–3).

Fig. 1. Photographic representation of the embalmed head, in front (on the left) and left-lateral (on the right) views. The images show the portions of bandages well preserved in the upper facial region, and the areas of exposure of the skin brown-black in colour. The superior cranial portion is exposed due to the loss of soft tissues and bandages. At the level of the mouth and nose, which has not been preserved, a resinous substance of shiny black colour is observed. In lateral norm, the preservation of the auricle is visible.
In the images, the scale bars equal 5 cm.

Radiological investigations

Tomographic images allowed visualizing the unwrapped aspect of the specimens, avoiding invasive interventions. The images of the head without bandages showed the degree of preservation of soft tissues. Viewing only the skeletal part, no breakages or fractures that altered its integrity were visible.

Images of the foot revealed the integrity of the skeletal portion and the preservation of joints in their anatomical position. The residual limb appeared in perfect articulation and irregularly broken at the metaphysis. Tomographic analyses of the hand showed the absence of some carpal bones, as it was macroscopically observed at the level of the wrist, of which only the trapezium, trapezoid and hamate bones were preserved.

Biological profile

Tomographic analyses of the finds suggested that the three embalmed human parts were not consistent with a single individual. Biological profiles of the three mummified portions are illustrated

Fig. 2. Photographic representation of the embalmed left foot, in lateral (on the left) and frontal (on the right) views. The preservation of the foot and of a distal residue of the left lower limb is observed. In lateral view, the pattern of bandages and the irregular section where the tibia and fibula are interrupted are appreciated. In frontal view, the preservation of the toes, of which the second and third are missing, deprived of the bandages with exposure of the blackish skin, is visible. In both standards, the preserved blue faience tubes and the presence of a white cementing substance coated in longitudinal and transverse bands along the back of the foot are observed.
In the images, the scale bars equal 5 cm. (For interpretation of the references to color in this figure legend, the reader is referred to the web version of this article.)

Fig. 3. Photographic representation of the embalmed left hand, in dorsal (on the left) and palmar (on the right) views. The preservation of the part, from the wrist throughout the hand up to the fingers, as well as the pattern of wrapping of the palm and of individual fingers, are shown. In dorsal view, a residue of a coating whitish material is observed on the radial side. At the lower right, some details of the weaving of the bandages are visible.
In the images, the scale bars equal 5 cm.

below.

Head

The features of the cranium pointed towards male sex: i) prominent supraorbital ridges, ii) rounded supraorbital margins, iii) sloping forehead, iv) absence of parietal eminences, v) vertical big mastoid processes, vi) development of nuchal line and external occipital eminence, vii) everted gonial angles and prominent chin (Fig. 4).

Some features, as the almost complete obliteration of the cranial sutures, the calcification of thyroid cartilages and the degree of dental wear suggested the advanced age of the subject (Fig. 5). In addition, a conspicuous ante-mortem teeth loss was observed, causing almost total edentulism, with the exception of three maxillary teeth and of the anterior mandibular teeth, reinforcing the hypothesis of an elderly individual (Figs. 4 and 5).

We also observed some noteworthy non-metric traits of the cranium, such as the bipartite Inca bone (or pre-interparietal bones) of the occipital squama and the elongated styloid process of the temporal bone (measuring about 4.2 cm).

Hand

The ossification of the hamate of the carpus allowed estimating an

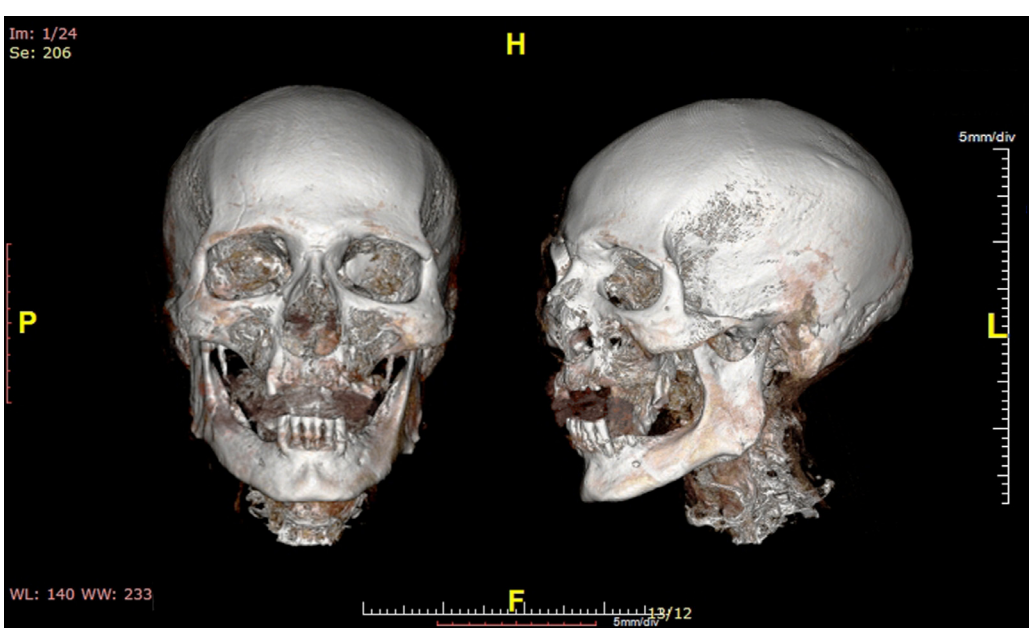

Fig. 4. Tomographic images of the head after the virtual unwrapping and the removal of soft tissues, frontal and fronto-lateral views. Features of the cranium suggesting male sex are visible. In particular, strong gonial eversion, prominent supraorbital ridges, sloping forehead, vertical big mastoid processes and prominent chin, are observed. A strong dental wear and a severe antemortem teeth loss, up to almost total edentulism, are also visible, suggesting an advanced age-at-death of the individual.

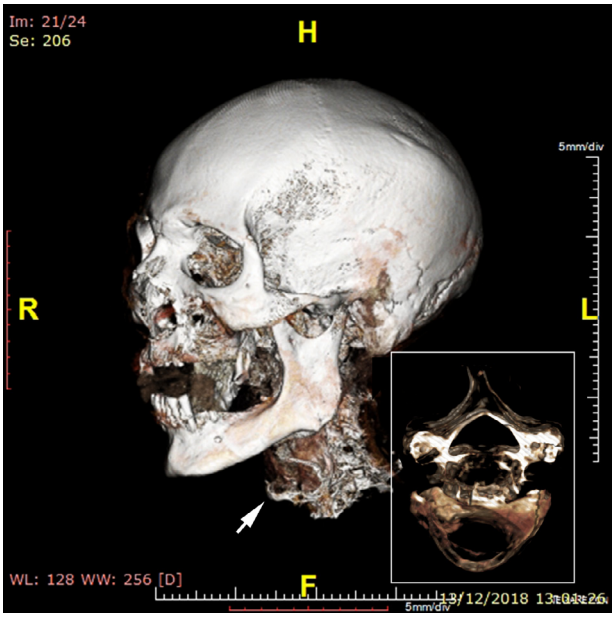

Fig. 5. Tomographic image of the head, left latero-anterior view. White arrow shows the calcification of the thyroid cartilage, suggesting an advanced age-at-death of the individual. At the lower right, a detail of the calcified cartilage in cross section is shown.

age greater than 10 years, while the lack of fusion of the epiphyses of the metacarpal heads and of the bases of the phalanges suggested an age-at-death not over 16 years (Fig. 6).

Foot

The absence of observable degenerative changes allowed us to hypothesize that the foot belonged to a young individual. More particularly, evidence of retention of the fusion line of the calcaneal tuberosity enabled suggesting an age range between 18 and 20 years (Fig. 6).

Embalming technique

Tomographic investigations revealed several significant features useful to the reconstruction of the embalming process.

Firstly, tomographic images of the head allowed visualizing the soft tissue preservation under the wrappings. Below the bandages, at the level of the mouth, the presence of filling elements of the oral cavity was also observed (Fig. 7).

By sectioning the three-dimensional reconstruction of the skull in transversal and sagittal views, it was possible to observe that the cribriform lamina of the ethmoid was incomplete and appeared broken (Fig. 8). The fracture of a portion of left lesser wing of the sphenoid bone was also highlighted. Tomographic images also revealed the presence in the cranial, oral and nasal cavities of a substance with a radiodense appearance that inside the skull was recognizable in the form of separated irregular fragments. This radiodense substance appeared to fill all accessible cavities of the head, from the nasal to the oral cavity up to the pharyngeal and laryngeal regions. The same appearance has been detected inside the cavities of the sphenoid sinus and ethmoid cells. Overall, this substance appeared adherent to the lower and posterior portions of the cavities (Fig. 8).

Paleopathological evidences

Only the mummified head showed pathological conditions.

At the level of the preserved cervical vertebrae, degeneration of the articular surfaces was observed, with formation of horizontal jutting spicules and reduction of intervertebral spaces. In sagittal section, the vertebrae appeared deformed, with hypertrophic changes at the level of the end plates of the bodies. Between the vertebral bodies of C4 and C5, in sagittal section, ring apophyses were not clearly visible and the two bodies seemed seamless united (Fig. 9).

The cranium showed evidence of bilateral thinning of the parietal bones. In particular, two circular areas of reduction in thickness of the cranial table were observed in the upper parietal portion, on the two sides of the sagittal suture and symmetrically to the parietal foramina. Particularly affected by the reduction in thickness was the external cranial table, which in sagittal and coronal section appeared reduced and resorbed, until almost uncovering the diploe. The two areas were also observed in the three-dimensional reconstruction, in the form of wide depressions of the surface (Fig. 10). In detail, the left area measured 2.73 (transverse diameter) X 2.83 (sagittal diameter) cm and the right one was 3.59 (transverse diameter) X 2.85 (sagittal diameter) cm. The normal cranial bone thickness (frontal, parietal unaffected) in other sections was 6.01, 6.94, 6.21, 6.15 mm. The cranial bone thickness in the two resorbed areas was at the right 3.99, 4.60, 4.86, 5.11 mm and at the left 4.38, 4.78, 5.05, 5.11 mm.

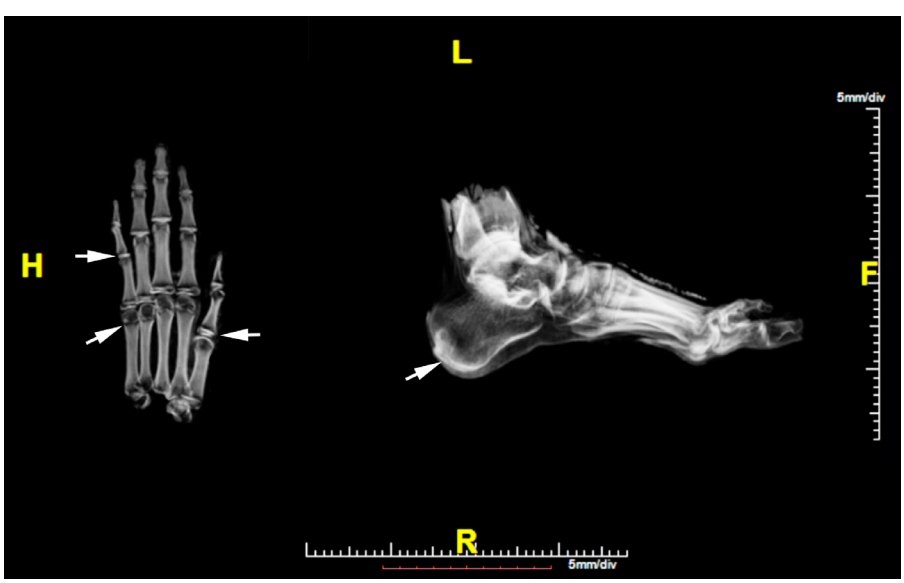

Fig. 6. Tomographic images of the left hand (on the left) and foot (on the right). On the left, white arrows indicate the fusion lines of the proximal epiphyses (bases) of the phalanges and of the distal epiphyses of the metacarpals (heads) of the left hand. On the right, white arrow indicates the still visible line of fusion of the calcaneal tuberosity.

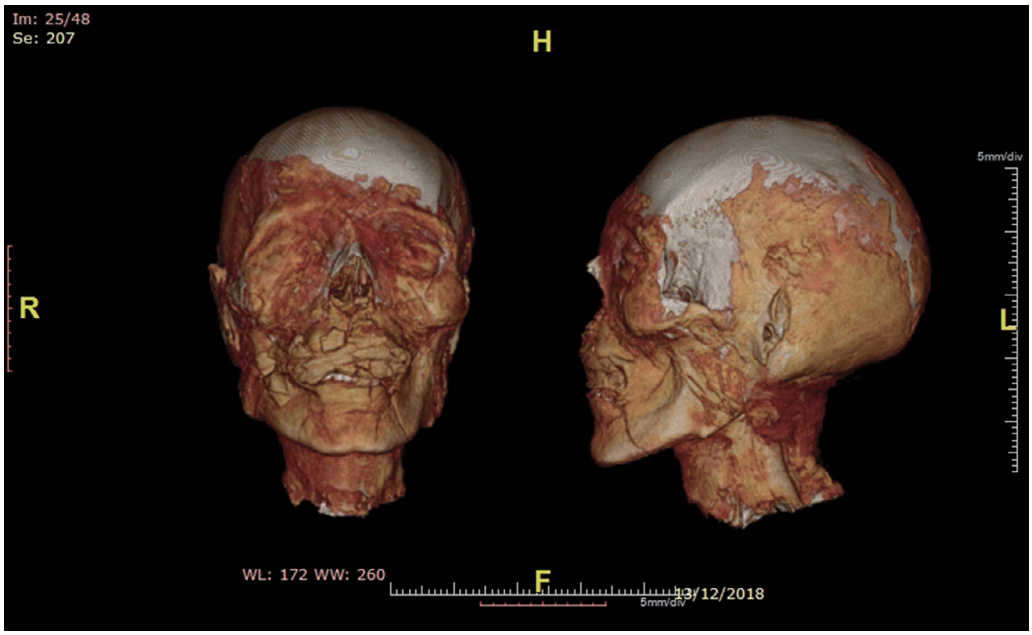

Fig. 7. Tomographic images of the mummified head, three-dimensional re-elaboration. Soft tissues preserved under the wrappings are recognizable. Obliteration of the oral cavity and partial cranial bones exposure, due to the loss of part of the mummified tissues, are observed. Inside the orbital cavities and in the posterior neck region some muscular structures preserved are shown.

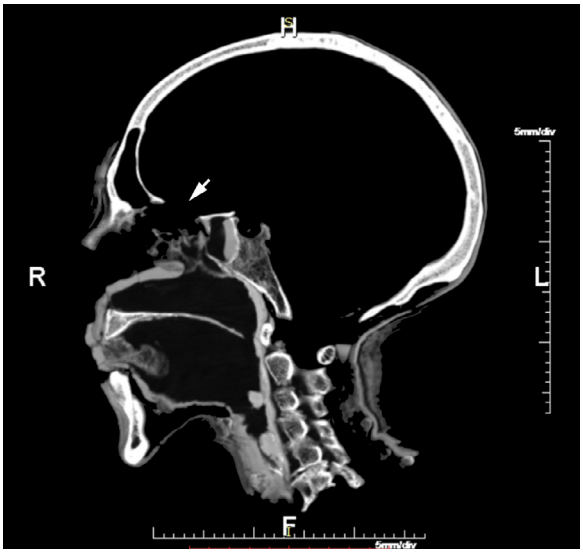

Fig. 8. Tomographic image of the mummified head, sagittal section. A radiodense material is shown to fill the cavities of the head. The substance, grey-opaque in colour, is observed adhering on the floor of the nasal and oral cavities, along the posterior wall of the pharyngeal and laryngeal tracts, inside the ethmoidal cells and along the posterior wall of sphenoidal sinuses. Breakage of the cribriform plate of the ethmoid bone is also shown (white arrow).

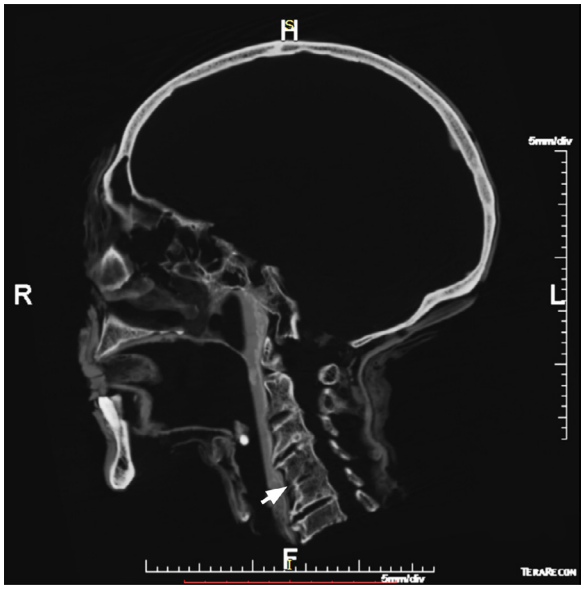

Fig. 9. Tomographic image of the mummified head, sagittal section. Vertebral joints degeneration, with formation of horizontal jutting spicules, reduction of intervertebral spaces and hypertrophic changes at the end plates of the vertebral bodies are appreciated. Between C4 and C5 ring apophyses are not clearly visible, showing a possible fusion of the two bodies (white arrow).

Discussion

Ancient Human remains are the "material memory" of the people who preceded us and, therefore, can provide a direct means by which we can learn much of our past. As custodians of this precious source of information on biological human history, we need the commitment to promote the long-term preservation of the archaeological collections to ensure that future generations will be able to learn from them and, therefore, know and understand those stories [32].

However, human remains are characterized and significantly differentiated from any other naturalistic remains due to the complex symbolic, anthropological, cultural, psychological and religious values they are capable of evoking on individuals and/or communities. These values urge a careful evaluation and a precise moral responsibility of the researchers and the museum institution with respect to several ethical issues arising from the comparison of different interests involved.

Although lagging behind what happened for clinical studies, in the last decades the ethical discussion has also concerned ancient human finds, with particular reference to: ways of their acquisition; lack of previous informed consent of the deceased, his descendants or the community to whom he belonged; respect for human dignity and bodily integrity; invasiveness of the investigations, which can irreparably compromise their conservation and consequently future studies; possible infringement of privacy and spread of "sensitive" data, respect for the religious and cultural traditions, appropriate communication research results, protection and accessibility of cultural heritage, museum exibition [26, 33].

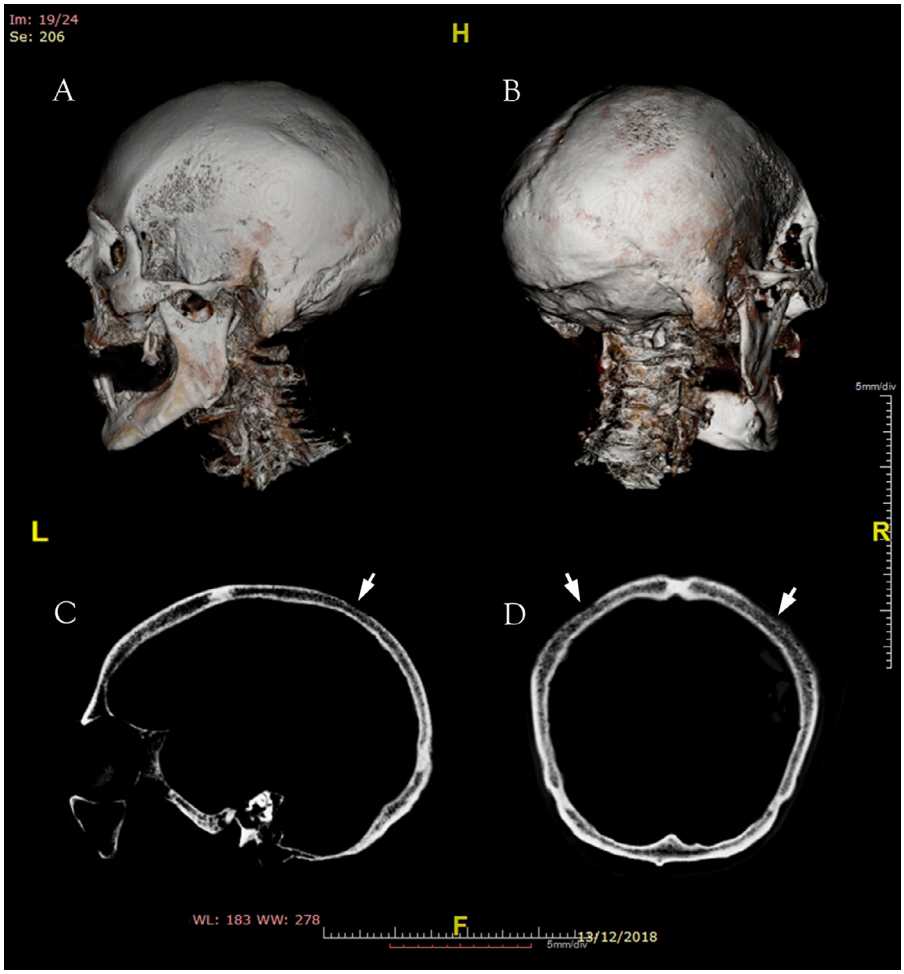

Fig. 10. Tomographic images of the mummified head, with representation of the resorptions at the level of parietal bones. (A, B) Left lateral aspect and right latero-posterior view of the head, two bilateral areas of resorption in the parietal bones are clearly recognisable in the form of two depressions with irregular aspect; (C) tomographic sagittal section of the head, showing the areas of resorption in the form of parietal thinning and exposure of the diploe after the gradual disappearance of the outer cortex (white arrow); (D) tomographic coronal slice displaying the section of the two areas of resorption and thinning of the parietals (white arrows).

The peculiarity of the nature of these remains is also indicated in the Code of Ethics of the International Council of Museums (ICOM), which inserted human remains in a special category titled "culturally sensitive materials", providing for a particular discipline for their management [34].

However, in Italy, the ethical debate on this issue is, to date, very recent and still, at least in part, unexplored question [35]. In fact, except the 2013 opinion on the donation of the *post mortem body*, the Italian National Bioethics Committee never addressed ethical issues relating to the detention, treatment and management of human remains. Even the literature on the topic is not very extensive in Italy [36]. This although Italian museums themselves have been invested by requests for returns of several human remains, as in the case of the famous Villella skull exhibited at the Cesare Lombroso Museum in Turin [37, 38].

As a "culturally sensitive material", human remains collections must be handled with respect regardless of their age and legitimacy of provenance. The issue on whether at all and how to study ancient mummies is subjected to new discussions.

Radiology is the only way to investigate human remains that still preserve mummified tissues [31, 39]. If we talk about Egyptian embalming, radiological investigation represents the most efficient way to analyse the find while maintaining its integrity [40, 41]. Radiological examinations allow us to analyse the finds without damage them and explore bandages, bones and other materials used for embalming [42, 43].

Thanks to the acquisition of radiological images it was possible to understand that those three mummified finds, exhibited inside the same shrine and described as "the mummy of Erba", may belong to three different subjects. In fact, the skull belonged to a male subject of advanced age, while the foot showed an age between 18 and 20 years and the hand was estimated between 10 and 16 years.

Overall, macroscopic external observation is the first step useful to investigate all the details of the embalmed portions. It was useful in our case in order to examine the weaving of the bandages, the aspect of the beads and of the material used to stuck them. Significant, in fact, are the considerations about the grave goods allowing to associate them with a historical period, and in particular place the finds within a dynasty. In particular, the presence of faience tubes on the foot bandages, according to what emerges from the Egyptian historiography, is known to have a magical protective purpose [44, 45]. This type of grave goods was in fact used to protect the deceased and guarantee their eternal survival. This custom can be found starting from the XXI dynasty but it also lasts until the XXVI dynasty and it seems to continue until the Ptolemaic period [46]. Probably preserved only in part, these beads seemed to have been much more numerous to adorn the foot in crossed longitudinal and transversal bands.

The hand does not preserve traces of grave goods but the kind of bandage recalls with great probability Egyptian origin. We know that this type of bandage, with the scruple of bandaging individually all the

fingers, represents an attention to detail in the mummification process that generally did not characterize the more recent periods, in which the bandage was coarser and for which the hand was entirely covered. Unfortunately, for this find it is not possible to add another interpretation.

However, it is on the skull where the successful embalming practice typical of Egyptians is highlighted. Firstly, computerized axial tomography allows us to see the rupture of the cribriform plate and the breaking of the sphenoid bone. This evidence is linked to the practice of excerebration of the brain, through the use of a hook that entered one of the nasal cavities to split the ethmoid and thus traced to the brain to completely remove it through manoeuvring within the cranial theca [47, 48].

The 3D re-elaboration of the tomographic images has also highlighted the presence, inside the skull, of a radiodense substance in the form of irregular fragments, probably following the crumbling of the crystallized material. This substance, which was also observed during the macroscopic examination, was also used with the aim of filling the cavities of the head. In fact, it was observed to be adhered to the floor of the oral and nasal cavities and along the posterior wall of the pharyngeal and laryngeal cavities, as well as inside the ethmoidal cells and along the posterior wall of the sphenoid sinuses. This suggests that the casting of the viscous substance must have taken place while the individual was in a supine position, which would have allowed the substance to flow along the cavities and crystallize along these portions. The scientific literature shows that, in the most ancient periods and not only in the Egyptian civilization, there were the uses of excerebrating the skull through the nose or by fracturing the occipital bone [49], in particular starting from the occipital foramen [41, 50]. In addition, Herodotus said that during the embalming process the brain was removed via the nostrils with an iron hook and what could not be reached with the hook was washed out with drugs [51]. In our case, it is the reference of the black resinous substance that allows a dating of the artefact to a period around the start of the XVIII dynasty. We also know that the excess use of black resinous substance is recorded even in the following periods, in particular between the late Dynastic and Roman age [52].

The radiological investigations suggest that for all the three finds the embalming must had been foreseen. It is evident that what has been described so far supports the authenticity of the finds. Indeed, it is difficult to imagine the reproduction of a fake with this kind of attention to detail, such as the filling of the skull cavities with resinous substances. Moreover, in case of reproductions of Egyptian mummies, tomography often unmasks the presence of brain matter.

For what concern pathological investigations, the evidences found on the parietals are significant. The condition of biparietal thinning, in fact, has been identified in more than 200 Egyptian skulls [53, 54].

This pathological condition appears to have been present elsewhere in the past and, albeit rarely recorded, is recognized also in today's clinic. In fact, several published paleopathological cases are documented in Europe (England, Italy, France, Austria and Spain), America, Africa and Australia. Biparietal thinning has been found even in India in a skull from the Bronze Age, which today would represent one of the oldest cases. This pathological condition has been known for a long time. In particular, the first descriptions of parietal thinning were published in the 18th century. Called by different names: “biparietal senile disease”, “senile arthropathy”, “biparietal thinning” and “parietal osteodystrophy”, with unknown etiology, this pathological condition appeared to usually involve the posterior parasagittal regions.

The manifestation of this anatomical alteration usually has an oval or quadrilateral flat shape that can measure up to 4 to 6 cm in the coronal plane and up to 8 or 9 cm in the parasagittal plane [55].

Cederlund et al. in the article published in 1982 reported a radiological observational criteria to classify the degree of the parietal thinning. In particular, based on the thickness of more affected bone, three stages were proposed: i) thinning is only superficially observed in the parietal region and in tomographical images a radiolucent area is highlighted; ii) a considerable thinning in anterior and posterior view is recorded, in particular the loss of more than half of the bone substance, even if the diploe is preserved, is observable; iii) external surface is affected and the total loss of the diploe and of the outer region is observed [56].

While true biparietal thinning seems to be characterized by a very subtle skull thickness and thin compact bone, this case shows regular wall thickness with reduced outer table until almost the exposure of the diploe, but without involvement of the inner table.

According to various authors, in the first phases of onset, only the outer table becomes flattened while inner table is unchanged [57]. Virchow believed that parietal thinning started as a localized disappearance of the superficial layers of the external skull table and gradually progressed through it, the diploe, and on occasion the inner table of the skull [58].

According to literature, this condition can manifest in two ways: flat or grooved. In particular, the second type involves a small area in the coronal plane and the thinning is created by a sagittal oriented groove. However, the most documented cases in literature are the “flat” types. Bruyn and Bots found a relationship between these two typologies, using the term “biparietal osteodystrophy” to indicate the second type [59].

From a radiological-morphological point of view, the normal convexity of the bone appears interrupted to form a superficial depression, which involves about a quarter of the parietal bone. Radiologically, on the lateral projection there is an area of reduced density corresponding to the region involved by bone thinning. As some authors report, magnetic resonance and computer tomography imaging show the thinning or the absence of the lamina corticalis externa, the loss or the disappearance of the diploe and an intact lamina corticalis interna in the area of the lesion [60–64].

From a histopathological point of view, some cases affected by thinning record the lack of osteoclasts [65].

At this point, we cannot avoid discussing the causes that are attributed to parietal thinning to date. For more than two centuries, anatomists, doctors and anthropologists have tried to find the answer to the etiological nature of this condition. The various causes associated over time include: constant pressure on the bones, developmental dysplasia, congenital dysplasia of the diploe, growth defects, post-menopausal osteoporosis, gonadal insufficiency, hormonal changes, inflammatory arthropathy associated with trauma, primary metastatic tumors, diabetes, senile changes of the temporal artery and simple anatomical variation.

By the clinical cases recorded, literature informs us that the most cases have a minimum average age of 50, for men, and over 60 for women. It can therefore be suggested that this condition is related to the reduction or cessation of sex hormone activity [66]. Hormonal disorder causes osteoporosis, a condition also linked to the lack of osteoclasts, especially in women of advanced age. However, it should be noted that bilateral parietal thinning has also been reported in young patients with hypogonadism, with or without osteoporosis, and also in young patients with other hormonal disorders. It is evident that also for our case to conclude a differential diagnostic reasoning is difficult, we can only record the presence of bilateral parietal thinning and, stating to the classification of degree, of the type one. Nothing else. We cannot establish what disease affected our subject, also considering the fact that we only have the subject's head.

It is certainly interesting to note how this condition has been highlighted in various Egyptian skulls. Smith recognized this condition in the skulls of the ancient Egyptians by describing it as “strange, large symmetrical depressions of the parietal bones” [67]. Furthermore, Rowling also noted this condition in the mummies of Thutmosis III and Meritamon of the New Kingdom [68].

Conclusion

Authenticating Egyptian finds is certainly not a simple operation. Especially if these come from private collections without documentation that certifies their discovery. If we then refer to human remains, the operation seems even more complicated, given both the fragile condition that characterizes these finds and the preservative provisions that they claim.

The study of human remains, especially those finds, such as mummies preserving tissues, cannot fail to take into account the use of radiology. Radiological imaging can in fact be not only a study tool on biological remains and ancient artefacts, but also an informative and communicative strategy capable of enhancing the museum display and interacting with the public. Paleoradiology would in fact have a high communicative value, we would say, of narration of the exposed find.

An efficient communicative power of these images that would enhance the find in a narrative dimension often distorted by the de-contextualization of a museum frame that is not exactly adequate as often happens.

Again, could not more recent grievances regarding the exposure of human remains be partially resolved by the support of the radiological images of some of the finds?

This, however, is another story. For now, let us worry about studying, thanks to the radiological support, also all those finds that, belonging to museum collections on the margins of large exhibitions, have not received the right attention. In fact, our case feels to be demonstrative of this need to stimulate a dialogue between the different disciplines to acquire a great deal of information: anthropological, archaeological and paleopathological.

So, we send our message, in the hope that this can also be heard by the curators of the small museums “Mummies outside their closets” - only temporarily to radiologically investigate them - and “Paleoradiological images inside museums”.

Acknowledgments

For radiological support, we thank Prof. Ugo Maspero and technician Dr. Luca Romano of the Division of Radiology, Casa di Cura Fondazione Gaetano e Piera Borghi.

References

[1] N. Lynnerup, Methods in mummy research, Anthropol. Anz. 67 (4) (2009) 357–384, https://doi.org/10.1127/0003-5548/2009/0028.
[2] A Cockburn, E Cockburn, TA Reyman, Mummies, Disease and Ancient Cultures, Cambridge University Press, Cambridge, 1998.
[3] M Licata, M Motto, B Grassi, P Badino, S Iorio, The space of man's death. A modern age secondary burial case in northern Italy, Homo 70 (2) (2019) 93–104, https://doi.org/10.1127/homo/2019/1077.
[4] M Licata, A Tosi, C Rossetti, S Iorio, The Bioarchaeology of Humans in Italy: development and issues of a discipline, Stud. Antiqu. et Archaeol. 24 (1) (2018) 119–130.
[5] M Licata, O Larentis, F Ventura, R Ciliberti, Mummified remains in the field of forensics. The comparison of a 19th century case report with current cases, Med. Hist. 3 (2) (2019) 99–104.
[6] Gruppioni G, Labate D, Mercuri L, Milani V, Traversari M, Vernia B. Gli scavi della Chiesa di San Paolo di Roccapelago dell'Appennino modenese. *La cripta con i corpi mummificati naturalmente. Pagani e cristiani.* Ed. All'insegna del Giglio: 219–45.
[7] WA Murphy Jr, Dz Nedden, P Gostner, R Knapp, W Recheis, H Seidler, The iceman: discovery and imaging, Radiology 226 (3) (2003) 614–629, https://doi.org/10.1148/radiol.2263020338.
[8] K. Spindler, The Man in the Ice: The Preserved Body of a Neolithic Man Reveals the Secrets of the Stone Age, Phoenix, London, 2001.
[9] N Lynnerup, Bog bodies, Anat. Rec. (Hoboken) 298 (6) (2015) 1007–1012, https://doi.org/10.1002/ar.23138.
[10] S Ry Andersen, P Geertinger, Bog bodies investigated in the light of forensic medicine, J. Danish Archaeol. 3 (1984) 111–119, https://doi.org/10.1080/0108464X.1984.10589916.
[11] D. Piombino-Mascali, Il maestro del sonno eterno, La Zisa, Palermo, 2009.
[12] A. Lucas, The use of natron in mummification, J. Egypt. Archeol. 18 (1932) 125–140, https://doi.org/10.2307/3854973.
[13] RC Garner, Experimental mummification, editor. in: AR David (Ed.), The Manchester Museum Mummy Project, Manchester University Press, Manchester, 1979, pp. 19–24.
[14] PL Fernández, J Esteban, A Franco, Paleopathology of soft tissues: what mummies can reveal, Pol. J. Pathol. 70 (1) (2019) 44–48, https://doi.org/10.5114/pjp.2019.84462.
[15] WR. Dawson, Making a mummy, J. Egypt. Archeol. 13 (1927) 40–49, https://doi.org/10.2307/3854360.
[16] RK. Chhem, Paleoradiology: imagining disease in mummies and ancient skeletons, Skelet. Radiol. 35 (11) (2006) 803–804, https://doi.org/10.1007/s00256-006-0144-y.
[17] M Licata, M Borgo, G Armocida, L Nicosia, E Ferioli, New paleoradiological investigations of ancient human remains from North West Lombardy archaeological excavations, Skelet. Radiol. 45 (3) (2016) 323–331, https://doi.org/10.1007/s00256-015-2266-6.
[18] M Licata, A Tosi, O Larentis, C Rossetti, S Lorio, A Pinto, Radiology of Mummies, Semin. Ultrasound CT MR 40 (1) (2019) 5–11, https://doi.org/10.1053/j.sult.2018.10.016.
[19] C Jackowski, S Bolliger, MJ Thali, Common and unexpected finding in mummies from ancient Egypt and South America as revealed by CT, Radiographics 28 (2008) 1477–1492, https://doi.org/10.1148/rg.285075112.
[20] M Licata, A Tosi, R Ciliberti, P Badino, A Pinto, Role of radiology in the assessment of skeletons from archeological sites, Semin. Ultrasound CT MR 40 (1) (2019) 12–17, https://doi.org/10.1053/j.sult.2018.10.003.
[21] R Fusco, O Larentis, B Cermesoni, A Ravagnan, C Tesi, The “Mummy of Erba”: A study proposal for the analysis of a mummified Egyptian specimen, Med. Hist. 2 (3) (2018) 163–165.
[22] Inventario Reperti, Civico Museo di Erba, E 421 Mummia.
[23] T. Baber Tessa, Ancient corpses as curiosities: mummy mania in the age of early travel, J. Anc. Egypt. Interconnect. 8 (2016) 60–98, https://doi.org/10.1186/s41747-018-0048-3.
[24] GB. Belzoni, Narrative of the Operations and Recent Discoveries in Egypt and Nubia, John Murray, London, 1820, pp. 156–158.
[25] RG. Beckett, Paleoimaging: A review of applications and challenges, Forensic Sci. Med. Pathol. 10 (2014) 423–436, https://doi.org/10.1007/s12024-014-9541-z.
[26] BM Kreissl Lonfat, IM Kaufmann, F Rühli, A code of ethics for evidence-based research with ancient human remains, Anat. Rec. 298 (2015) 1175–1181, https://doi.org/10.1002/ar.23126.
[27] G Acsadi, J. Nemeskeri, History of Human Life Span and Mortality, Akademiai Kiado, Budapest, 1970.
[28] L Scheuer, S. Black, Developmental Juvenile Osteology, Elsevier Academic, San Diego, 2000.
[29] RS Meindl, CO Lovejoy, Ectocranial suture closure: a revised method for the determination of skeletal age at death based on the lateral-anterior sutures, Am. J. Phys. Anthropol. 68 (1) (1985) 57–66, https://doi.org/10.1002/ajpa.1330680106.
[30] CO. Lovejoy, Dental wear in the Libben population: its functional pattern and role in the determination of adult skeletal age at death, Am. J. Phys. Anthropol. 68 (1) (1985) 47–56, https://doi.org/10.1002/ajpa.1330680105.
[31] S Panzer, S Ketterl, R Bicker, S Schoske, AG Nerlich, How to CT scan human mummies: Theoretical considerations and examples of use, Int. J. Paleopathol. 26 (2019) 122–134, https://doi.org/10.1016/j.ijpp.2019.06.005.
[32] MA Katzenberg, AL. Grauer, Biological Anthropology of the Human Skeleton, third edition, Wiley Blackwell, 2019.
[33] IM Kaufmann, FJ. Rühli, Without 'informed consent'? Ethics and ancient mummy research, J. Med. Ethics 36 (2010) 608–613.
[34] International Council of Museums, ICOM Code of Ethics for Museums, Icom, 2006.
[35] M Licata, A Bonsignore, R Boano, F Monza, E Fulcheri, R Ciliberti, Study, conservation and exhibition of human remains: the need of a bioethical perspective, Acta Biomed. (2020) in press.
[36] R Ciliberti, A Bonsignore, A Molinelli, F Ventura, M Licata, How Italy Has moved from anatomical studies in the sixteenth century to body donation in the twenty-first century, Ann. Ital. Chir. 91 (2020) 1–7.
[37] R Ciliberti, G Armocida, Licata M Rebury the “Atavistic Skull” Studied by Lombroso? Am. J. Forensic Med. Pathol. (2019), https://doi.org/10.1097/PAF.0000000000000460.
[38] R Ciliberti, F Monza, F De Stefano, M Licata, The trial of the skull studied by the founder of criminal anthropology: the war of the Lombroso museum, J. Forensic Leg. Med. 59 (2018) 13–15.
[39] AJ Nelson, AD. Wade, Impact: Development of a radiological mummy database, Anat. Rec. 298 (2015) 941–948, https://doi.org/10.1002/ar.23130.
[40] SN Saleem, Z. Hawass, Variability in brain treatment during mummification of royal Egyptians dated to the 18th-20th dynasties: MDCT findings correlated with the archaeologic literature, AJR Am. J. Roentgenol. 200 (4) (2013) W336–W344, https://doi.org/10.2214/AJR.12.9405.
[41] E. Strouhal, Embalming excerebration in the Middle Kingdom, editor, in: RA David (Ed.), Science in Egyptology, Manchester University Press, Manchester, 1986, pp. 141–154.
[42] W Russel, AT Storey, PV Ponitz, Radiographic techniques in the study of the mummy, editor, in: JE Harris, EF Wente (Eds.), An X-ray Atlas of the Royal Mummies, University of Chicago, Chicago, 1980, pp. 163–187.
[43] FJ Rühli, RK Chhem, T Böni, Diagnostic paleoradiology of mummified tissue: interpretation and pitfalls, Can. Assoc. Radiol. J. 55 (2004) 218–227 PMID: 15362344.
[44] G Abdel-Maksoud, AR. El-Amin, A review on the materials used during the mummification processes in Ancient Egypt, Mediterr. Archaeol. Archaeometry 11 (2011) 129–150.
[45] B Geßler-Löhr, Mumia vera aegypticaim Abendland, editors. in: M Fitzenreiter, CE Loeben (Eds.), Die ägyptische Mumie – ein Phänomen der

Kulturgeschichte.Internet-Beiträge zur Ägyptologie und Sudanarchäologie. 1998 Berlin,.
[46] A Tchapla, P Méjanelle, J Bleton, S Goursaud, Characterisation of embalming materials of a mummy of the ptolemaic era. Comparison with balms from mummies of different eras, J. Sep. Sci. 27 (3) (2004) 217–234.
[47] H Hoffman, PA. Hudgins, Head and skull base features of nine Egyptian mummies: evaluation with high-resolution CT and reformation techniques, AJR 178 (2002) 1367–1376, https://doi.org/10.1002/jssc.200301607.
[48] J Cockitt, A Lamb, R Metcalfe, An Ideal Solution? Optimising pretreatment methods for artificially mummified ancient Egyptian tissues, Rapid Commun. Mass Spectrom. (2019), https://doi.org/10.1002/rcm.8686.
[49] R Seiler, F. Rühli, A unique case of perforated bilateral parietal bone thinning in a Third Intermediate Period Egyptian mummy (Geneva Museum D 0242), JEA J. Egypt. Archaeol. 100 (2014) 467–474, https://doi.org/10.1177/030751331410000124.
[50] Z Peacock, PH Chapman, R Gupta, L Kaban, Replication of ancient Egyptian osteotomies of the facial skeleton: insights into the mummification process, Int. J. Oral. Max. Surg. 40 (2011) 1332, https://doi.org/10.1016/j.ijom.2011.05.017.
[51] Herodotus, The Histories, Oxford University Press, Oxford, 2008, pp. 105–115 Waterfield R, translator.
[52] AD Wade, AJ Nelson, GJ Garvin, A synthetic radiological study of brain treatment in ancient Egyptian mummies, Homo 62 (2011) 248–269, https://doi.org/10.1016/j.jchb.2011.01.004.
[53] GE. Smith, The causation of the symmetrical thinning of the parietal bones in ancient Egyptians, J. Anat. Physiol. 41 (Pt 3) (1907) 232–233 PMCID: PMC1289120.
[54] SR. Phillips, Cranial anomaly, pathology, or normal variant? Thin parietal bones in ancient Egyptian human remains, (2007) DissertationDissertations available from ProQuest. AAI3292064.
[55] JD Camp, LA. Nash, Developmental thinnes of the parietal bones, Radiology 42 (1994) 42, https://doi.org/10.1148/42.1.42.
[56] CG Cederlund, L Adnren, H Olivecrona, Progressive Bilateral Thinning of the Parietal Bones, Skelet. Radiol. 8 (1982) 29–33, https://doi.org/10.1007/bf00361365.
[57] G Wilms, W Van Roost, J Van Russelt, J Smits, Biparietal thinning: correlation with CT findings, Radiologe 23 (8) (1983) 385–6 PMID: 6622672.
[58] R Virchow, Uber die Involutionskrankheit (Malum senile) der platten Knochen, Verh. Phys. Med. Ges. Würzburg 4 (1854) 354.
[59] GW Bruyn, GTAM Bots, Biparietal osteodystrophy, Clin. Neurol. Neurosurg. 80 (1978) 125–128, https://doi.org/10.1016/s0303-8467(78)80035-3.
[60] SY Luk, JSF Shum, JKW Chan, JLS Khoo, Bilateral thinning of the parietal bones: a case report and a review of radiological features, Pan Afr. Med. J. 4 (2010) 7.
[61] S Takata, S Takao, S Yoshida, F Hayashi, N Yasui, Therapeutic effects of one-year alendronate treatment in three cases of osteoporosis with parietal thinning of the skull. Case report, J. Med. Invest. 55 (2008) 297–302.
[62] S Tsutsumi, Y Yasumoto, M Ito, Idiopathic calvarial thinning. Case report, Neurol. Med. Chir. (Tokyo) 48 (2008) 275–278.
[63] MB Yilmaz, E Egemen, B Özbakir, A Tekiner, Epidural haematoma aft er minor trauma on patient with biparietal osteodistrophy, J. Koren Neurosurg. Soc. 53 (2013) 57–58.
[64] M Henneberg, RJ Henneberg, M Cipriani, Bilateral symmetrical thinning of the parietals in a female from santa venera necropolis of ancient Poseidonia, Italy (5th Century BC), Paleopathol. Newslett. 118 (2002) 11–15.
[65] MB Schmidt, Atrophie und Hypertrophie des Knochens einschliesslich der Osteosklerose. InHenke and Lubarsch: Hanbuch der speziellen pathologishen Anatomie und Histologie, Springer, Berlin, 1937, pp. 5–10.
[66] BS. Epstein, The concurrence of parietal thinness with postmenopausal, senile, or idiopathic osteoporosis, Radiology 60 (1) (1953) 29–35, https://doi.org/10.1148/60.1.29.
[67] GE. Smith, The Royal Mummies, Bath Press, London, 2000.
[68] JT. Rowling, Pathological changes in mummies, Proc. R. Soc. Med. 54 (1961) 409–415.