Forensic Imaging 24 (2021) 200432

Contents lists available at ScienceDirect

Forensic Imaging

journal homepage: www.sciencedirect.com/journal/forensic-imaging

Case report

Star-trail artifacts of the advanced-putrefied brain on postmortem CT

Tomoya Kobayashi [a,b,*], Moyu Yamamori [c], Seiji Shiotani [d], Tomokazu Numano [b], Yoshiyuki Ishimori [a], Shinji Abe [a], Hideyuki Hayakawa [e]

[a] Department of Radiological Sciences, Ibaraki Prefectural University of Health Sciences Japan
[b] Department of Radiological Sciences, Graduate School of Human Health Sciences, Tokyo Metropolitan University Japan
[c] Department of Radiological Technology, Tsukuba Medical Center Hospital Japan
[d] Department of Radiology, Seirei Fuji Hospital Japan
[e] Department of Forensic Medicine, Tsukuba Medical Examiner's Office Japan

A B S T R A C T

We report star-trail artifacts of advanced-putrefied brain on postmortem CT (PMCT) of a 77-year-old male approximately one month after death. After CT calibration, routine PMCT (tube current time product: 400 mAs) showed star-trail artifacts, which arose due to cerebral cavitation, but were hardly visible on low-dose PMCT (100 mAs) due to noise. Low-dose PMCT with 4-time-image summation also showed star-trail artifacts. Those are not due to mechanical X-ray detector problems.

Introduction

Postmortem computed tomography (PMCT) of an advanced-putrefied brain shows cerebral cavitation due to liquification of the decayed brain and gas generated from putrefaction [1-3]. Occasionally, we see artifacts which mimic star-trails on a starry landscape photograph (looks similar to ring artifacts) in the advanced-putrefied brain. The authors named this type of artifact as a star-trail artifact. However, to our knowledge, there are no published papers regarding this phenomenon. Ring artifacts on CT generally occur due to mechanical problems of the X-ray detector from inadequate maintenance or inaccurate calibration [4]. Thus, a lack of understanding of reasons for an occurrence of star-trail artifacts in advanced putrefied brain on PMCT may lead to misunderstandings that the phenomenon is a result of mechanical problems of the X-ray detector, with attempts to repair or replace parts or an entire CT unit. Herein, we report star-trail artifacts observed in advanced-putrefied brain with PMCT.

Materials and methods

A 77-year-old male found dead in a bath-tub, having been submerged for approximately one month after death, underwent PMCT at our institution using a 16-row-detector CT scanner (Aquilion Lightning; Canon Medical Systems, Otawara, Japan) dedicated solely for corpses. Before PMCT, the CT scanner was calibrated using air and water phantoms to reduce various artifacts. Table 1 shows the PMCT scan parameters of the head.

Results

Routine PMCT (tube current time product: 400 milliampere-second (mAs)(window level/width = 40/80)) showed star-trail artifacts, similar to ring artifacts, which arose from cavities of the advanced-putrefied brain (Fig. 1). These were hardly visible on low-dose PMCT (100 mAs) due to the increased noise and the filtered back projection reconstruction method (Fig. 2). Fused PMCT with 4 times image summation of low-dose PMCT (window level/width = 160/320) [5] (Fig. 3), equivalent to the radiation dose of routine PMCT (100 mAs × 4 = 400 mAs), also showed star-trail artifacts similar to those in Fig. 1.

Discussion

As the reason of star-trail artifacts, a mechanical problem could be excluded since the CT scanner was well-calibrated before scanning the subject. Two causes may be considered for star-trail artifacts of the advanced-putrefied brain on PMCT, both of which are related to intracranial cavitation in an advanced decayed body. One is an edge gradient effect which results in streak artifacts due to marked differences in CT density between gas (cavity) and surrounding soft tissue (brain parenchyma). However, the edge gradient effect does not explain ring shape. The second is that the X-ray absorption distribution differs from predicted image adjustment settings. Generally, CT scanners are designed to

This study was presented at the 8th annual meeting of the International Society of Forensic Radiology and Imaging, March, 2019, Berlin, Germany.

* Corresponding author.
E-mail address: kobayashito@ipu.ac.jp (T. Kobayashi).

https://doi.org/10.1016/j.fri.2021.200432
Received 3 December 2020; Received in revised form 17 December 2020; Accepted 7 January 2021
Available online 14 January 2021

Table 1
Scanning and reconstruction parameters of routine PMCT and low-dose PMCT for the head.

	Routine PMCT	Low-dose PMCT
Tube voltage (kV)	120	
Tube current (mA)	200	50
Single collimation width (mm)	1	
Total collimation width (mm)	16	
Slice thickness (mm)	4	
Scan mode	Conventional scan mode	
Data collection diameter (mm)	320	
Rotation time (sec/rotation)	2	
Adaptive Iterative Dose Reduction	No	
Reconstruction kernel	FC26	

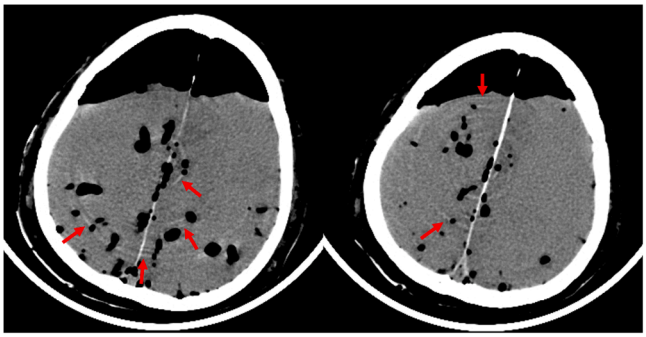

Fig. 1. Routine postmortem CT of the advanced-putrefied brain (200 mA × 2 sec = 400 mAs (window level/width = 40/80))
Star-trail artifacts caused by intracranial cavity for the decayed brain are seen (arrows).

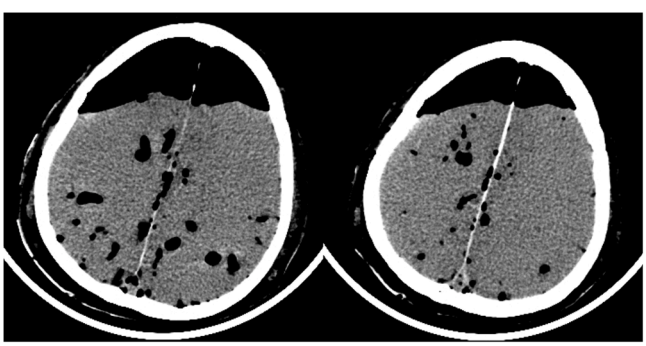

Fig. 2. Low-dose postmortem CT of the advanced-putrefied brain (50 mA × 2 sec = 100 mAs (window level/width = 40/80))
Compared with Fig. 1, star-trail artifacts are hardly visible due to increased noise.

image relatively columnar-shaped objects that are filled with solid contents. To show sudden CT value changes arising from multiple small cavities in a decayed brain, components for the high spatial frequency must be correctly expressed [5]. Therefore, star-trail artifacts might have been caused by aliasing due to misidentification of spatial frequency in combination with the filtered back projection reconstruction method [6]. In PMCT, high radiation doses to obtain high quality images are not an issue because over-radiation is not a problem with corpses [7-9]. For cerebral CT of a living person, an approximate 300 mAs is used for auto-exposure control. The mAs value of Fig. 1 was 400 mAs (200 mA × 2 s), which was higher than that for a living body. The star-trail artifacts were hardly visible when the mAs value was lowered

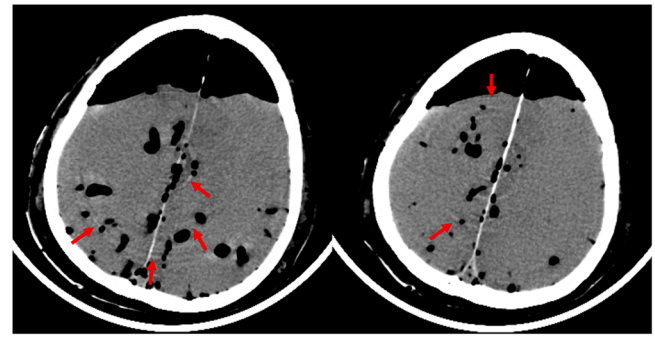

Fig. 3. Postmortem CT with four-times image summation (50 mA × 2 sec × 4 = 400 mAs (window level/width = 160/320))
Star-trail artifacts similar to those of Fig. 1 are seen (arrows).

to 100 mAs (low-dose CT)(50 mA × 2 s)(Fig. 2) due to the increased noise, but appeared again with fused CT at 4-times image summation under the same scan conditions at brain window setting (window level/width = 160/320), because the CT number (Hounsfield Units: HU) of fused CT was 4 times that of low-dose postmortem CT (50 mA × 2 s × 4 = 400 mAs)(Fig. 3). In our study, while a high radiation dose improved image quality, artifacts increased. Therefore, further studies regarding causes and reproducibility of star-trail artifacts are necessary, as well as seeking for optimal scan conditions to reduce star-trail artifacts, such as utilization of iterative reconstruction methods.

In conclusion, causes for star-trail artifacts of the putrefied brain on PMCT do not include mechanical problems of the X-ray detector.

Declaration of Competing Interest

This work is supported by a Grant-in-Aid for Scientific Research (KAKENHI # 20K18984) from the Japan Society for the Promotion of Science (JSPS).

Acknowledgement

The authors thank Ms. Yumiko Moriyama for her help with manuscript preparation.

References

[1] G Cartocci, A Santurro, M Neri, et al., Post-mortem computed tomography (PMCT) radiological findings and assessment in advanced decomposed bodies, Radiol. Med. 124 (10) (2019) 1018–1027.
[2] J Tschui, C Jackowski, N Schwendener, et al., Post-mortem CT and MR brain imaging of putrefied corpses, Int. J. Legal Med. 130 (4) (2016) 1061–1068.
[3] C Egger, P Vaucher, F Doenz, et al., Development and validation of a postmortem radiological alteration index: the RA-Index, Int. J. Legal Med. 126 (4) (2012) 559–566.
[4] JF Barrett, N. Keat, Artifacts in CT: recognition and avoidance, Radiographics 24 (6) (2004) 1679–1691.
[5] HP. Hiriyannaiah, X-ray computed tomography for medical imaging, IEEE Signal Process Mag. 14 (2) (1997) 42–59.
[6] K Sato, M Shidahara, M Goto, et al., Aliased noise in X-ray CT images and band-limiting processing as a preventive measure, Radiol. Phys. Technol. 8 (2) (2015) 178–192.
[7] T Kobayashi, H Fukuoka, S Suzuki, et al., Fused CT-Improved image quality of coronary arteries on postmortem CT by summation of repeated scans, Forensic Imaging (2020), 200386.
[8] T Kobayashi, M Yoshida, T Numano, et al., Noise reduction effect of computed tomography by image summation method (fused CT): phantom study, Forensic Imaging (2020), 200418.
[9] D Gascho, MJ Thali, T. Niemann, Post-mortem computed tomography: technical principles and recommended parameter settings for high-resolution imaging, Med. Sci. Law 58 (1) (2018) 70–82.